



DATE PRESENTING CLINICAL SIGNS

2.6.26

PATIENT

Tootsie Ochoa

SPECIES

Feline

BREED

Siamese

SEX

FS

AGE

12.14.10

WEIGHT

6.9lbs

INTERPRETED BY

Maggie Machen Lamy,
DVM, DACVIM
(Cardiology)

HOSPITAL NAME

Greenbrier VC

REFERRING VET

Dr. Boccanfuso

INVOICE

46731

History: Elevated BNP: 600. No murmur. IBD; managed on Budesonide and probiotics. Assess prior to anesthesia.

-Pertinent abnormal PE/Chem/CBC/UA Results: BNP: 603; rest of CBC/Chemistry/T4 unremarkable. UA-USG 1.020 rest unremarkable

-Current medications: budesonide 1 mg SID since Jan 2024, proviable daily

-Sedation used: Not required to complete full diagnostic ultrasound.

-Pertinent previous ultrasound results: No previous.

-STAT: Not requested.

-Imaging performed by: Stephanie Warga RDCS, RVT.

ECHOCARDIOGRAM FINDINGS

2D, m-mode, color flow and doppler imaging is available. The left ventricular wall is mildly increased in dimension. There is a mildly hyperechoic endocardium consistent with fibrosis. Mild symmetric papillary muscle hypertrophy and remodeling. The right ventricle is subjectively normal in size and morphology. There is no left atrial enlargement present. No right atrial enlargement present. Normal RVOT velocity. Trace TR. Normal LVOT velocity. There is no obvious systolic anterior motion (SAM) of the mitral valve present. No MR. No significant AI or PI. There is no pericardial effusion noted. No pleural effusion appreciated. No obvious cardiac tumors.

CARDIAC CHART

FELINE CARDIAC PARAMETERS	BODY WEIGHT (kg)	HR (BPM)	IVSd (cm) (Moise, Pipers)	LVIDd (cm) (Moise, Pipers)	LVWd (cm) (Moise, Pipers)	FS (%)	EF (%)
NORMAL PARAMETER	-----	150-240	3.5-0.55	<2 (mean 1.5)	3.5-0.55	35-67	80-100
PATIENT	3.1	NM	0.65	1.1	0.69	45	80
FELINE CARDIAC PARAMETERS	LA/AO (Boon)	LA/AO HEART BASE (Swe) (Abbott)	LA 2D short axis Base view (cm) (Abbott)		LVOT VEL (m/s)	RVOT VEL (m/s)	E max (m/s)
NORMAL	<1.5	<1.3	<1.2		<1.6	<1.3	<0.9
PATIENT	NM	1.2	1.3		1.3	1.5	NM

Adapted from June Boon, Veterinary Echocardiography, 1998
Abbott J & MacLean H JVIM 2006;20: 111-119, Moise et al. Am J Vet Res 47:1476, 1986. Pipers et al. Am J Vet Res 40:882, 1979.

INTERPRETATION OF THE FINDINGS & FURTHER RECOMMENDATIONS

Hypertrophic cardiomyopathy (HCM) is a rule out diagnosis once a patient is deemed normotensive and euthyroid. Both should be ruled out in this case as contributing factors. The degree of disease is mild, with only mild LVH and no LA dilation. This would indicate the risk for clinical issues is low at this

time. Flow through the great vessels is normal, and no significant valve regurgitation is seen. No additional pathology is identified.

No medications are typically indicated prior to significant atrial dilation, as many cats will experience naturally slow progression. It is important to note that no medications have been shown to definitively alter long term outcome at this stage, particularly in the absence of SAM. *Regarding the newly available drug Felycin-CA1:* Recent data reports that Felycin-CA1 may improve the degree of LV hypertrophy in some cats with naturally occurring subclinical HCM. The clinical benefit is currently unknown and is still being investigated. The HALT trial is actively enrolling HCM cats all over the US in order to acquire prospective data on a larger sample size of cats. Should you wish to use the medication, the published dose is 0.3mg/kg weekly, and the drug should be avoided in cats with advanced cardiac changes, diabetes, non-healing wounds, active infections or liver disease. The medication is an immunosuppressant and should be used with caution. For further information, please visit www.triviumvet.com.

Long term prognosis is guarded for subclinical HCM, with a great deal of variability in rate of progression. The REVEAL study showed that approximately 7% of asymptomatic cats with HCM will develop CHF or a cardiogenic thrombus within 1 year, 20% within 5 years, and ~30% within 10 years. Close monitoring for progressive LA dilation going forward will help better predict long term outcome.

Monitor at home for any respiratory issues or signs of blood clot events (neurologic change, paralysis, etc.).

Anesthetic risk is considered mildly elevated; however, judicious fluid administration is advised if needed with careful monitoring to screen for fluid overload. A reasonable protocol includes opioid/benzodiazepine premedication, propofol induction, isoflurane maintenance. Avoid ketamine, telazol, acepromazine and Dexdomitor. Additionally, drugs that stimulate heart rate should be avoided unless clinically necessary (glycopyrrolate, atropine).

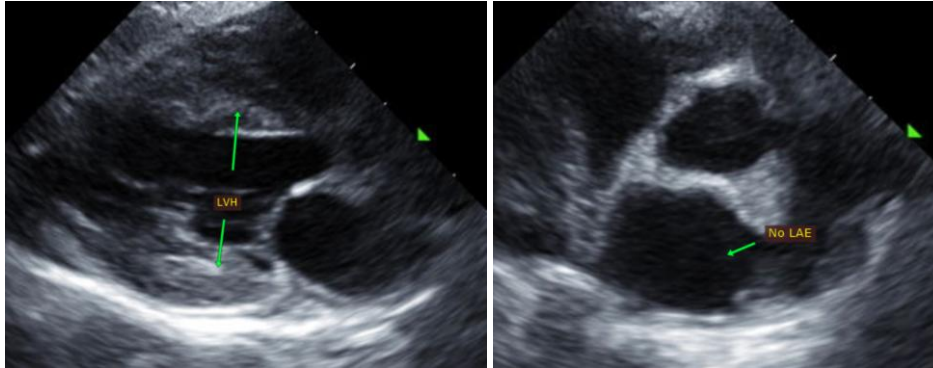
Risk for complication with steroid or fluid use typically follows LA dilation, which in this case is mildly elevated. If needed, monitoring of RR/RE is advised particularly in the initiation phase.

PLAN

A screening blood pressure and T4 are recommended every 6 months lifelong.

A recheck echocardiogram is recommended in 6 months to assess for progression, sooner if any issues arise in the interim.

IMAGES



The information and recommendations provided are based on the images presented by the referring veterinarian. No evaluation can be communicated regarding pathology that was not visible in the image/video clips provided.

Thank you for this referral. This report was generated using transcription software, and minor dictation errors may be present. If the clinical or image interpretation does not parallel your findings or if I can be of any further assistance, please contact me.

Maggie Machen Lamy, DVM
Diplomate of the American College of Veterinary Internal Medicine (Cardiology)
info@sonopath.com